

# A Positive Tinel Sign as Predictor of Pain Relief or Sensory Recovery after Decompression of Chronic Tibial Nerve Compression in Patients with Diabetic Neuropathy

A. Lee Dellon, M.D., Ph.D.<sup>1,2</sup> Vicki L. Muse, R.N., B.S.N., C.D.E.<sup>2</sup> D. Scott Nickerson, M.D.<sup>3</sup> et al\*

<sup>1</sup> Department of Plastic Surgery, Johns Hopkins University, Baltimore, Maryland

<sup>2</sup> Dellon Institute for Peripheral Nerve Surgery, Peripheral Nerve Towson, Baltimore, Maryland

<sup>3</sup> Northeast Wyoming Wound Care Center, Sheridan, Wyoming

\* Contributing authors listed at the end of the article.

**Address for correspondence and reprint requests** A. Lee Dellon, M.D., Ph.D., The Exchange Bldg, Suite 18, 1122 Kenilworth Drive, Towson, MD 21204  
(e-mail: ALDellon@Dellon.com).

J Reconstr Microsurg 2012;28:235–240.

## Abstract

Predictive ability of a positive Tinel sign over the tibial nerve in the tarsal was evaluated as a prognostic sign in determining sensory outcomes after distal tibial neurolysis in diabetics with chronic nerve compression at this location. Outcomes were evaluated with a visual analog score (VAS) for pain and measurements of the cutaneous pressure threshold/two-point discrimination. A multicenter prospective study enrolled 628 patients who had a positive Tinel sign. Of these patients, 465 (74%) had VAS >5. Each patient had a release of the tarsal tunnel and a neurolysis of the medial and lateral plantar and calcaneal tunnels. Subsequent, contralateral, identical surgery was done in 211 of the patients (152 of which had a VAS >5). Mean VAS score decreased from 8.5 to 2.0 ( $p < 0.001$ ) at 6 months, and remained at this level for 3.5 years. Sensibility improved from a loss of protective sensation to recovery of some two-point discrimination during this same time period. It is concluded that a positive Tinel sign over the tibial nerve at the tarsal tunnel in a diabetic patient with chronic nerve compression at this location predicts significant relief of pain and improvement in plantar sensibility.

## Keywords

- ▶ Tinel sign
- ▶ diabetic neuropathy
- ▶ neurolysis

In 2004, a retrospective study of 46 patients with diabetic neuropathy evaluated the presence or absence of a positive Tinel sign on sensory outcome, dichotomized into good/excellent versus fair/poor results, from a tibial neurolysis in the four medial ankle tunnels.<sup>1</sup> At 1 year, the presence of a positive Tinel sign had a sensitivity of 88%, a specificity of 50%, and a positive predictive value of 88% in identifying patients who would have a good/excellent outcome.<sup>1</sup> In that study, only 33% of the patients with a negative Tinel sign recovered good/excellent results from surgical decompression. While the technical details of the surgical approach have been reviewed,<sup>2,3</sup> the prognostic value of the positive Tinel sign

remains to be prospectively studied in a large, carefully defined population of patients with diabetes.

## Methods

This study was designed as a prospective, multicentered study, with a well-defined sample of patients and well-defined outcomes.

Each of the 38 surgeons participating in this study were trained in an Advanced Lower Extremity Peripheral Nerve Surgery Workshop so that each surgeon used the same operative technique as previously described and reviewed.<sup>2,3</sup>

received  
August 13, 2011  
accepted  
October 16, 2011  
published online  
March 12, 2012

Copyright © 2012 by Thieme Medical Publishers, Inc., 333 Seventh Avenue, New York, NY 10001, USA.  
Tel: +1(212) 584-4662.

DOI <http://dx.doi.org/10.1055/s-0032-1306371>.  
ISSN 0743-684X.

### Inclusion Criteria

1. Patient had to have diabetes requiring medication for glycemic control.
2. The patient's diabetes was in good glycemic control, as determined by their primary care physician.
3. Patient had to have symptomatic diabetic neuropathy, defined as a diffuse, symmetrical, distal, large fiber, and polyneuropathy.<sup>4-6</sup>
4. This neuropathy had to be documented at least by neurosensory testing with the pressure-specified sensory device (PSSD).<sup>7-10</sup>
5. If the patient had pain, defined as a Visual Analog Scale score  $>5$ , then there had to be a trial and failure of neuropathic pain medication.<sup>11,12</sup>
6. Patients had sufficient lower extremity blood supply, as demonstrated either by a palpable dorsalis pedis or posterior tibialis pulse, or, in the absence of a palpable pulse, an ankle/brachial index  $>0.70$ .
7. Absence of pedal edema.
8. Physical findings consistent with a chronic nerve compression at the known sites of anatomic narrowing, that is, common peroneal nerve at the fibular tunnel, deep peroneal nerve over the dorsum of the foot, and tibial nerve compression in the tarsal tunnel, as demonstrated by a positive Tinel sign.<sup>1</sup>
9. Patient had to be sufficiently healthy to have a 2-hour general anesthetic.

### Exclusion Criteria

1. Weight over 300 pounds.
2. Previous lower extremity peripheral nerve surgery.
3. Previous amputation.

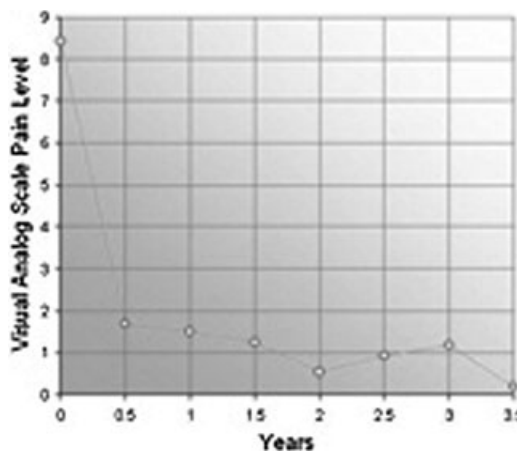
### Outcome Analysis

1. Assessment of pain on a 10-point visual analog scale at the outset of patient entry and then at 6-month intervals for 3.5 years.
2. Sensibility evaluation using the PSSD (Sensory Management Services, LLC, Baltimore, Maryland) was done at study entry, and at 6 month intervals for 3.5 years.
3. Statistical analysis was done using Kaplan–Meier proportional hazard analysis and student's *t*-test.

### Results

At the time of data analysis, 628 patients had been enrolled in the study and followed for at least 1 year. Of these, 211 had the contralateral limb operated upon for a total number of operated limbs of 839. Of the 628 patients, 465 (74%) had pain  $>5$  at the initial visit, and 152 of these patients had a second limb operated upon for a total of 617 operated limbs with pain. Data analysis extends from the initial onset to 3.5 years postoperatively.

The results of relief of pain are given in ►Fig. 1. Of the 617 operated limbs in diabetics who had pain  $>5$  at time of data entry, the mean VAS pain level was 8.5 and at 6 months

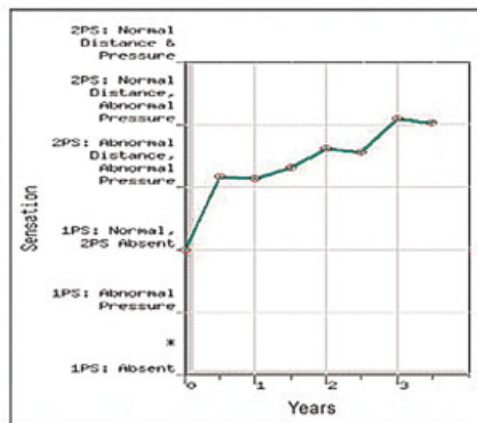


**Figure 1** Outcome: Pain. Of the 617 limbs in diabetics who had pain  $>5$  at time of data entry, the mean VAS pain level was 8.5 and at 6 months after surgery had decreased to 2.0 ( $p < 0.001$ ). The mean pain level remained between 2 and 1 for the remainder of the study.

after the surgery decreased to 2.0 ( $p < 0.001$ ). The mean pain level remained between 2 and 1 for the remainder of the study.

The results for recovery of sensibility are given in ►Fig. 2. Of the 839 limbs that were operated upon, the mean entry level sensibility was that the one-point static touch (1PS) was present and normal, but two-point static touch was absent (2PS) as measured with the PSSD. Following surgery, there was a progressive improvement in sensation, with some 2PD being recovered at 1 year with the pressure threshold required for discriminating one from two points still being abnormal. At 2 years, mean 2PD had returned to normal range, but the pressure threshold remained abnormal. The mean sensibility did not return to normal.

### RECOVERY OF 1-POINT AND 2-POINT SENSATION



**Figure 2** Outcome: Sensation. Of the 839 limbs that were operated upon, the mean entry level sensibility was that one-point static touch (1PS) was present and normal, but two-point static touch (2PS) was absent as measured with the PSSD. Following surgery, there was a progressive improvement in sensibility.

## Discussion

The results of this Level I, prognostic study, demonstrate that the presence of a positive Tinel sign over the tibial nerve in the tarsal tunnel in a patient with diabetes predicts that neurolysis of the tibial nerve and its branches at the foot and ankle level will most likely result in relief of pain and recovery of sensibility. The methodology employed in this study, a multicentered prospective study, including Podiatric Foot and Ankle Surgeons, Plastic Surgeons, and Hand Surgeons, permits generalization of these results due to the multifaceted and geographical diversity of the patient population. The well-defined patient population permits further confidence in the value of the positive Tinel sign in predicting relief of pain and recovery of sensibility in the diabetic who has neurolysis of an entrapped tibial nerve and its branches at the foot and ankle level.

In 1992, the first clinically reported Therapeutic Level IV study of the results of peripheral nerve decompression in the diabetics with chronic nerve compression, in the upper and lower extremity, used the presence of a positive Tinel sign as an inclusion criteria.<sup>13</sup> The next two Therapeutic Level IV studies on this subject, one involving relief of pain<sup>14</sup> and the other involving restoration of sensation,<sup>15</sup> were less clear on the inclusion criteria of a positive Tinel sign, and although the surgical technique reported was that of the first study, the surgeons were not trained in that specific technique. The subsequent therapeutic level IV studies all used the identical surgical technique as that reported in the present study, and required a positive Tinel sign as an inclusion criteria. These studies have in common the finding of an average 80% of the patients achieving pain relief and 80% recovering sensibility.<sup>16-22</sup> A prospective, blinded, Therapeutic Level III study,<sup>23</sup> comparing the success of surgical decompression in one leg of a diabetic and compared the outcome at a mean of 23 months with the sensibility of the contralateral, non-decompressed leg, found that the surgical decompressed legs had improved sensibility significantly ( $p < 0.001$ ). That study also used a positive Tinel sign as an inclusion criteria. Taken together, the past literature supports the use of a positive Tinel as a prognostic sign for identifying a patient with diabetes who can expect a good to excellent outcome from neurolysis of the tibial nerve and its branches at the foot and ankle levels.

What is the pathophysiology behind the positive Tinel to predict a patient who will benefit from neurolysis? In 1984, I suggested that the patient's-positive response to percussion over a peripheral nerve indicates that axon sprouts are regenerating in this region, whether the nerve is the one that has been surgically repaired or the one that is-repairing itself during nerve compression. In very early nerve compression, the Tinel sign would be negative. As the compression continues, the majority of these patients will have a positive Tinel sign. In advanced compression, with muscle atrophy and loss of two-point discrimination, Tinel sign is often negative because no further regeneration is occurring.<sup>24</sup> Experimental models of chronic compression in the rat<sup>25</sup> and monkey<sup>26</sup> demonstrate progressive demyelination, and then loss of

large myelinated nerve fibers. These findings have been corroborated in the histopathology of human specimens of tarsal tunnel syndrome<sup>27</sup> and radial sensory nerve compression.<sup>28</sup> Recently, using more acute models of nerve compression, it has been shown that the earliest stages already have demyelination which induces axonal sprouting at the site of compression.<sup>29,30</sup> Therefore, the Tinel sign now has a firm pathophysiological basis with regard to identifying a site of nerve compression.

A potential source of error using a Tinel sign is whether different surgeons will do the test in a similar manner. The variable of concern is how hard the examiner taps over the nerve. Clearly, a given force can be found to make even a normal nerve hurt when applied near a bony prominence or tunnel. A recent study sheds light upon this subject.<sup>31</sup> It was found that there is a great variability in the force applied by different examiners when tapping a force transducer as if they were percussing a nerve during the examination of the carpal tunnel. However, there was not much variance within the taps for a given examiner. It might be appropriate then to evaluate the actual force that would be required to evoke a positive Tinel in a group of patients with clinical nerve entrapment syndromes, in different anatomic locations.

It is concluded that the Tinel sign is a useful predictor of relief of pain and recovery of sensibility in patients with diabetes who have chronic tibial nerve compression at the foot and ankle. The absence of a standardized force of application of the Tinel sign by the different surgeons in this multicenter study did not affect the results of using the Tinel sign in clinical practice.

### Note

Presented to American Diabetes Association 66th Scientific Sessions meeting, San Francisco, 2008.

### Conflict of Interest

A Lee Dellon, M.D., Ph.D. owns Sensory Management Services, LLC, which markets the Pressure-Specified Sensory Device.

### \*Contributing Authors

Thomas Akre, DO, Orthopedic Surgery, Mishasawka, Indiana.

Sharon R. Anderson, DPM, Podiatric Foot & Ankle Surgery, Rolla, Missouri.

Steve L Barrett, DPM, MBA, Podiatric Foot & Ankle Surgery, Houston, Texas.

Kent R. Biddinger, MD, Orthopedic Foot & Ankle Surgery, Midland, Michigan.

Peter J. Bregman, DPM, Podiatric Foot & Ankle Surgery, Tewksbury, Massachusetts.

Bryan P. Bullard, DPM, Podiatric Foot & Ankle Surgery, Amarillo, Texas.

Damien M. Dauphinee, DPM, Podiatric Foot & Ankle Surgery, Denton, Texas.

James M. DeJesus, DPM, Podiatric Foot & Ankle Surgery, Naugatuk, Connecticut.

Ramon A. DeJesus, MD, Plastic Surgery, Bel Air, Maryland.

A. Lee Dellon, MD, Plastic Surgery, Johns Hopkins University, Baltimore, Maryland.

Ivica Dusic, MD, Plastic Surgery, Georgetown University, Washington, DC.

Jeffery Dunkerly, DPM, Podiatric Foot & Ankle Surgery, York, Pennsylvania.

Michael R. Galina, DPM, Podiatric Foot & Ankle Surgery, Winter Garden, Florida.

Virginia Hung, MD, Plastic Surgery, Winchester, Massachusetts.

Dolf R. Ichtertz, MD, Orthopedic Hand Surgery, North Platte, Nebraska.

Michael F. Kutka, MD, Plastic Surgery, Newburyport, Massachusetts.

Richard P Jacoby, DPM, Podiatric Foot & Ankle Surgery, Scottsdale, Arizona.

J. Barry Johnson, DPM, Podiatric Foot & Ankle Surgery, Winston-Salem, North Carolina.

David W. Mader, DPM, Podiatric Foot & Ankle Surgery, Naugatuk, Connecticut.

Christopher T. Maloney, Jr, MD, Plastic Surgery, Tucson, Arizona.

Peter J. Mancuso, DPM, Podiatric Foot & Ankle Surgery, Brentwood, New York.

R. Craig Martin, DPM, Podiatric Foot & Ankle Surgery, York, Pennsylvania.

Rick F. Martin, DPM, Podiatric Foot & Ankle Surgery, York, Pennsylvania.

Brian A. McDowel, DPM, Podiatric Foot & Ankle Surgery, Carmichael, California.

Vito J. Rizzo, DPM, Podiatric Foot & Ankle Surgery, Bayshore, Long Island, NY.

Michael Rose, MD, Plastic Surgery, Shrewsbury, New Jersey.

Gedge D. Rosson, MD, Plastic Surgery, Johns Hopkins University, Baltimore, Maryland.

Bruce B. Shafiroff, MD, Plastic Surgery, Syracuse, New York.

Jerome K. Steck, DPM, Podiatric Foot & Ankle Surgery, Tucson, Arizona.

Raymond G. Stolarski, DPM, Podiatric Foot & Ankle Surgery, Cincinnati, Ohio.

Patrick Swier, MD, Plastic Surgery, Lewes, Delaware.

Tatiana A. Wellens-Bruschayt, DPM, PhD, Pod. Foot & Ankle Surg., Winter Haven, Fla.

Bronwyn Wilke, DPM, Podiatric Foot & Ankle Surgery, York, Pennsylvania.

Eric H. Williams, MD, Plastic Surgery, Johns Hopkins University, Baltimore, Maryland.

Michael A. Wood, DPM, Podiatric Foot & Ankle Surgery, Chicago, Illinois.

William A. Wood, DPM, Podiatric Foot & Ankle Surgery, Chicago, Illinois.

Michael P. Younes, DPM, Podiatric Foot & Ankle Surgery, York, Pennsylvania.

Fuat Yuksel, MD, Plastic Surgery, Istanbul, Turkey.

## References

- Lee CH, Dellon AL. Prognostic ability of Tinel sign in determining outcome for decompression surgery in diabetic and nondiabetic neuropathy. *Ann Plast Surg* 2004;53(6):523-527
- Dellon AL. The Dellon approach to neurolysis in the neuropathy patient with chronic nerve compression. *Handchir Mikrochir Plast Chir* 2008;40:1-10
- Dellon AL. Surgical treatment of chronic nerve compression in the patient with neuropathy. In: Zgonnis T, ed. *Surgical Reconstruction of the Diabetic Foot and Ankle*. Philadelphia: Lippincott Williams & Wilkins; 2009
- Dyck PJ. Peripheral neuropathy. Changing concepts, differential diagnosis and classification. *Med Clin North Am* 1968;52(4):895-908
- Vinik AI, Mehrabyan A. Diabetic neuropathies. *Med Clin North Am* 2004;88(4):947-999, xi
- Sinnreich M, Taylor BV, Dyck PJ. Diabetic neuropathies. Classification, clinical features, and pathophysiological basis. *Neurologist* 2005;11(2):63-79
- Tassler PL, Dellon AL. Cutaneous pressure thresholds in ulcerated and non-ulcerated diabetic feet, measured with the Pressure-specified Sensory Device. *J Am Pod Med Assoc* 1995;85:679-684
- Tassler PL, Dellon AL. Correlation of measurements of pressure perception using the pressure-specified sensory device with electrodiagnostic testing. *J Occup Environ Med* 1995;37(7):862-866
- Dellon AL. Computer-assisted sensibility evaluation and surgical treatment of tarsal tunnel syndrome. *Adv Pod* 1996;2:17-40
- Tassler PL, Dellon AL. Pressure perception in the normal lower extremity and in the tarsal tunnel syndrome. *Muscle Nerve* 1996;19(3):285-289
- Vinik AI. Advances in diabetes for the millennium: new treatments for diabetic neuropathies. *MedGenMed* 2004;6(3, Suppl):13-19
- Rathur HM, Boulton AJ. Recent advances in the diagnosis and management of diabetic neuropathy. *J Bone Joint Surg Br* 2005;87(12):1605-1610
- Dellon AL. Treatment of symptomatic diabetic neuropathy by surgical decompression of multiple peripheral nerves. *Plast Reconstr Surg* 1992;89(4):689-697, discussion 698-699
- Wiemann TJ, Patel VG. Treatment of hyperesthetic neuropathic pain in diabetics. Decompression of the tarsal tunnel. *Ann Surg* 1995;221(6):660-664, discussion 664-665
- Hollis Caffee H. Treatment of diabetic neuropathy by decompression of the posterior tibial nerve. *Plast Reconstr Surg* 2000;106(4):813-815
- Wood WA, Wood MA. Decompression of peripheral nerves for diabetic neuropathy in the lower extremity. *J Foot Ankle Surg* 2003;42(5):268-275
- Biddinger KR, Amend KJ. The role of surgical decompression for diabetic neuropathy. *Foot Ankle Clin* 2004;9(2):239-254
- Rader AJ. Surgical decompression in lower-extremity diabetic peripheral neuropathy. *J Am Podiatr Med Assoc* 2005;95(5):446-450
- Valdivia JM, Dellon AL, Weinand ME, Maloney CT Jr. Surgical treatment of peripheral neuropathy: outcomes from 100 consecutive decompressions. *J Am Podiatr Med Assoc* 2005;95(5):451-454
- Yao Y, Wang RZ. Peripheral Nerve Decompression (Dellon Procedure) and Diabetic Neuropathy. *Chinese J Med* 2005;10:1756-1758

- 21 Siemionow M, Alghoul M, Molski M, Agaoglu G. Clinical outcome of peripheral nerve decompression in diabetic and nondiabetic peripheral neuropathy. *Ann Plast Surg* 2006;57(4):385–390
- 22 Karagoz H, Yuksel F, Ulkur E, Celikoz B. Early and late results of nerve decompression procedures in diabetic neuropathy: a series from Turkiye. *J Reconstr Microsurg* 2008;24(2):95–101
- 23 Aszmann OC, Kress KM, Dellon AL. Results of decompression of peripheral nerves in diabetics: a prospective, blinded study. *Plast Reconstr Surg* 2000;106(4):816–822
- 24 Dellon AL. Tinel or not Tinel. *J Hand Surg [Br]* 1984;9(2):216
- 25 Mackinnon SE, Dellon AL, Hudson AR, Hunter DA. Chronic nerve compression—an experimental model in the rat. *Ann Plast Surg* 1984;13(2):112–120
- 26 Mackinnon SE, Dellon AL, Hudson AR, Hunter DA. A primate model for chronic nerve compression. *J Reconstr Microsurg* 1985;1(3):185–195
- 27 Mackinnon SE, Dellon AL, Daneshvar A. Histopathology of the tarsal tunnel syndrome: examination of a human tibial nerve. *Contemp Orthop* 1984;9:43–48
- 28 Mackinnon SE, Dellon AL, Hudson AR, Hunter DA. Histopathology of compression of the superficial radial nerve in the forearm. *J Hand Surg Am* 1986;11(2):206–210
- 29 Gupta R, Rowshan K, Chao T, Mozaffar T, Steward O. Chronic nerve compression induces local demyelination and remyelination in a rat model of carpal tunnel syndrome. *Exp Neurol* 2004;187(2):500–508
- 30 Gupta R, Rummler LS, Palispis W, et al. Local down-regulation of myelin-associated glycoprotein permits axonal sprouting with chronic nerve compression injury. *Exp Neurol* 2006;200(2):418–429
- 31 Lifchez SD, Means KR Jr, Dunn RE, Williams EH, Dellon AL. Intra- and inter-examiner variability in performing Tinel's test. *J Hand Surg Am* 2010;35(2):212–216

